

AIS PennHIP

(877) 727-6800

www.antechimaging.com

Owner's Copy

PennHIP Report

Referring Veterinarian: Dr Jordan Mogen
Email: squawpeakanimalhospital@yahoo.com

Clinic Name: Squaw Peak Animal Hospital
Clinic Address: 3165 East Lincoln Drive Suite 115

Phoenix, AZ 85016

Phone: (602) 553-8855

Fax: (602) 553-0188

Patient Information

Client: Palmer, Shannon

Patient Name: Gunstock Doodles Maggie

Reg. Name: N/A

PennHIP Num: 173001

Species: Canine

Date of Birth: 17 Nov 2021

Sex: Female

Date of Study: 04 May 2022

Date of Report: 05 May 2022

Tattoo Num: N/A

Patient ID: 9288539255 Maggie

Registration Num: N/A

Microchip Num: 900079000930262

Breed: MIXED BREED

Age: 6 months

Weight: 20.4 lbs/9.3 kgs

Date Submitted: 04 May 2022

Findings

Distraction Index (DI): Right DI = 0.50, Left DI = 0.50.

Osteoarthritis (OA): No radiographic evidence of OA for either hip.

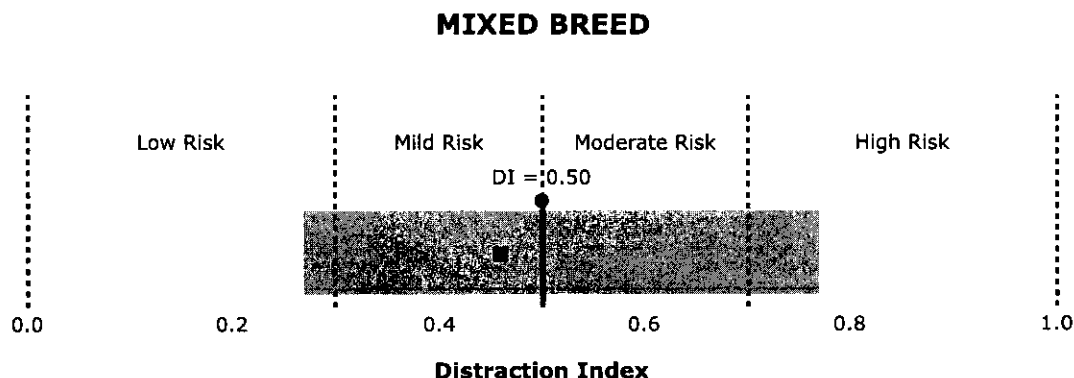
Cavitation/Other Findings: No cavitation present.

Interpretation

Distraction Index (DI): The laxity ranking is based on the hip with the greater laxity (larger DI). In this case the DI used is 0.50.

OA Risk Category: The DI is between 0.50 and 0.69. This patient is at moderate risk for hip OA.

Distraction Index Chart:



BREED STATISTICS: This interpretation is based on a cross-section of 11456 canine patients of the MIXED BREED breed in the AIS PennHIP database. The gray strip represents the central 90% range of DIs (0.27 - 0.77) for the breed. The breed average DI is 0.46 (solid square). The patient DI is the solid circle (0.50).

SUMMARY: The degree of laxity (DI = 0.50) falls within the central 90% range of DIs for the breed. This amount of hip laxity places the hip at a moderate risk to develop hip OA. No radiographic evidence of OA for either hip.